

World Journal of *Orthopedics*

World J Orthop 2017 December 18; 8(12): 853-967



EDITORIAL

- 853 Update on mesenchymal stem cell therapies for cartilage disorders
Paschos NK, Sennett ML

MINIREVIEWS

- 861 New insights in the treatment of acromioclavicular separation
van Bergen CJA, van Bommel AF, Alta TDW, van Noort A
- 874 Transforaminal Percutaneous Endoscopic Discectomy using Transforaminal Endoscopic Spine System technique: Pitfalls that a beginner should avoid
Kapetanakis S, Gkasdaris G, Angoules AG, Givissis P

ORIGINAL ARTICLE

Basic Study

- 881 Role of fast-setting cements in arthroplasty: A comparative analysis of characteristics
Caraan NA, Windhager R, Webb J, Zentgraf N, Kuehn KD
- 891 Augmented reality: The use of the PicoLinker smart glasses improves wire insertion under fluoroscopy
Hiranaka T, Fujishiro T, Hida Y, Shibata Y, Tsubosaka M, Nakanishi Y, Okimura K, Uemoto H

Case Control Study

- 895 Season of the year influences infection rates following total hip arthroplasty
Rosas S, Ong AC, Buller LT, Sabeh KG, Law T, Roche MW, Hernandez VH

Retrospective Cohort Study

- 902 Do Not Resuscitate status as an independent risk factor for patients undergoing surgery for hip fracture
Brovman EY, Pisansky AJ, Beverly A, Bader AM, Urman RD
- 913 Anterolateral rotatory instability *in vivo* correlates tunnel position after anterior cruciate ligament reconstruction using bone-patellar tendon-bone graft
Tashiro Y, Okazaki K, Murakami K, Matsubara H, Osaki K, Iwamoto Y, Nakashima Y

Retrospective Study

- 922 Evaluation of 1031 primary titanium nitride coated mobile bearing total knee arthroplasties in an orthopedic clinic
Breugem SJM, Linnartz J, Sierevelt I, Bruijn JD, Driessen MJM

- 929 Acetabular cup version modelling and its clinical applying on plain radiograms

Denisov A, Bilyk S, Kovalenko A

Observational Study

- 935 Deepening trochleoplasty combined with balanced medial patellofemoral ligament reconstruction for an adequate graft tensioning

von Engelhardt LV, Weskamp P, Lahner M, Spahn G, Jerosch J

SYSTEMATIC REVIEWS

- 946 Antibiotic bone cement's effect on infection rates in primary and revision total knee arthroplasties

Kleppel D, Stirton J, Liu J, Ebraheim NA

- 956 Systematic review of bone marrow stimulation for osteochondral lesion of talus - evaluation for level and quality of clinical studies

Yasui Y, Ramponi L, Seow D, Hurley ET, Miyamoto W, Shimozono Y, Kennedy JG

CASE REPORT

- 964 Acute compartment syndrome of the thigh following hip replacement by anterior approach in a patient using oral anticoagulants

Hogerzeil DP, Muradin I, Zwitser EW, Jansen JA

ABOUT COVER

Editorial Board Member of *World Journal of Orthopedics*, Chunfeng Zhao, MD, Professor, Research Scientist, Department of Orthopedic Surgery, Mayo Clinic, Rochester, MN 55905, United States

AIM AND SCOPE

World Journal of Orthopedics (*World J Orthop*, *WJO*, online ISSN 2218-5836, DOI: 10.5312) is a peer-reviewed open access academic journal that aims to guide clinical practice and improve diagnostic and therapeutic skills of clinicians.

WJO covers topics concerning arthroscopy, evidence-based medicine, epidemiology, nursing, sports medicine, therapy of bone and spinal diseases, bone trauma, osteoarthropathy, bone tumors and osteoporosis, minimally invasive therapy, diagnostic imaging. Priority publication will be given to articles concerning diagnosis and treatment of orthopedic diseases. The following aspects are covered: Clinical diagnosis, laboratory diagnosis, differential diagnosis, imaging tests, pathological diagnosis, molecular biological diagnosis, immunological diagnosis, genetic diagnosis, functional diagnostics, and physical diagnosis; and comprehensive therapy, drug therapy, surgical therapy, interventional treatment, minimally invasive therapy, and robot-assisted therapy.

We encourage authors to submit their manuscripts to *WJO*. We will give priority to manuscripts that are supported by major national and international foundations and those that are of great basic and clinical significance.

INDEXING/ABSTRACTING

World Journal of Orthopedics is now indexed in Emerging Sources Citation Index (Web of Science), PubMed, PubMed Central and Scopus.

FLYLEAF

I-III Editorial Board

EDITORS FOR THIS ISSUE

Responsible Assistant Editor: *Xiang Li*
Responsible Electronic Editor: *Ya-Jing Lu*
Proofing Editor-in-Chief: *Lian-Sheng Ma*

Responsible Science Editor: *Li-Jun Cui*
Proofing Editorial Office Director: *Xiu-Xia Song*

NAME OF JOURNAL
World Journal of Orthopedics

ISSN
 ISSN 2218-5836 (online)

LAUNCH DATE
 November 18, 2010

FREQUENCY
 Monthly

EDITORS-IN-CHIEF
Quanjun (Trey) Cui, MD, Professor, Department of Orthopaedic Surgery, School of Medicine, University of Virginia, Charlottesville, VA 22908, United States

Bao-Gan Peng, MD, PhD, Professor, Department of Spinal Surgery, General Hospital of Armed Police Force, Beijing 100039, China

EDITORIAL BOARD MEMBERS
 All editorial board members resources online at <http://www.wjgnet.com>

www.wjgnet.com/2218-5836/editorialboard.htm

EDITORIAL OFFICE
 Xiu-Xia Song, Director
World Journal of Orthopedics
 Baishideng Publishing Group Inc
 7901 Stoneridge Drive, Suite 501, Pleasanton, CA 94588, USA
 Telephone: +1-925-2238242
 Fax: +1-925-2238243
 E-mail: editorialoffice@wjgnet.com
 Help Desk: <http://www.f6publishing.com/helpdesk>
<http://www.wjgnet.com>

PUBLISHER
 Baishideng Publishing Group Inc
 7901 Stoneridge Drive,
 Suite 501, Pleasanton, CA 94588, USA
 Telephone: +1-925-2238242
 Fax: +1-925-2238243
 E-mail: bpgoffice@wjgnet.com
 Help Desk: <http://www.f6publishing.com/helpdesk>
<http://www.wjgnet.com>

PUBLICATION DATE
 December 18, 2017

COPYRIGHT
 © 2017 Baishideng Publishing Group Inc. Articles published by this Open-Access journal are distributed under the terms of the Creative Commons Attribution Non-commercial License, which permits use, distribution, and reproduction in any medium, provided the original work is properly cited, the use is non commercial and is otherwise in compliance with the license.

SPECIAL STATEMENT
 All articles published in journals owned by the Baishideng Publishing Group (BPG) represent the views and opinions of their authors, and not the views, opinions or policies of the BPG, except where otherwise explicitly indicated.

INSTRUCTIONS TO AUTHORS
<http://www.wjgnet.com/bpg/gerinfo/204>

ONLINE SUBMISSION
<http://www.f6publishing.com>

Acute compartment syndrome of the thigh following hip replacement by anterior approach in a patient using oral anticoagulants

Dirk Pieter Hogerzeil, Imraan Muradin, Eline W Zwitser, Joris A Jansen

Dirk Pieter Hogerzeil, Imraan Muradin, Eline W Zwitser, Joris A Jansen, Department of Orthopedic Surgery, Alrijne Hospital, Leiderdorp, GA 2353, The Netherlands

ORCID number: Dirk Pieter Hogerzeil (0000-0002-1559-2657); Imraan Muradin (0000-0002-6059-4862); Eline W Zwitser (0000-0002-7412-5258); Joris A Jansen (0000-0001-6593-8815).

Author contributions: All authors contributed to the acquisition of the writing and revision of this manuscript.

Informed consent statement: The participating patient in this case report provided informed consent and gave permission for publication of the case.

Conflict-of-interest statement: None of the authors have any conflicts of interest to declare.

Open-Access: This article is an open-access article which was selected by an in-house editor and fully peer-reviewed by external reviewers. It is distributed in accordance with the Creative Commons Attribution Non Commercial (CC BY-NC 4.0) license, which permits others to distribute, remix, adapt, build upon this work non-commercially, and license their derivative works on different terms, provided the original work is properly cited and the use is non-commercial. See: <http://creativecommons.org/licenses/by-nc/4.0/>

Manuscript source: Unsolicited manuscript

Correspondence to: Dirk Pieter Hogerzeil, MD, Department of Orthopedic Surgery, Alrijne Hospital, Simon Smitweg 1, Leiderdorp, GA 2353, The Netherlands. dphogerzeil@alrijne.nl
Telephone: +31-6-22376633

Received: September 21, 2017
Peer-review started: September 22, 2017
First decision: November 7, 2017
Revised: November 13, 2017
Accepted: December 3, 2017
Article in press: December 3, 2017
Published online: December 18, 2017

Abstract

Acute compartment syndrome (ACS) of the thigh following primary total hip arthroplasty (THA) is a highly uncommon complication and has not yet been reported before with regards to the anterior approach through the anterior supine interval. We present a case of a 69-year-old male patient with a history of stroke, who developed ACS of the thigh after elective THA while using therapeutic low molecular weight heparin as bridging for regular oral anticoagulation. ACS pathogenesis, diagnostic tools, treatment and relevant literature are discussed. The patient's ACS was recognized in time and treated by operative decompression with fasciotomy of the anterior compartment. Follow-up did not show any neurological deficit or soft-tissue damage.

Key words: Orthopedics; Total hip arthroplasty; Anterior supine intermuscular approach; Acute compartment syndrome; Anticoagulation therapy

© **The Author(s) 2017.** Published by Baishideng Publishing Group Inc. All rights reserved.

Core tip: Acute compartment syndrome of the thigh is an uncommon complication following total hip arthroplasty, which has not yet been reported after hip replacement by anterior approach through the anterior supine interval. Global increase in venous thromboembolism chemoprophylaxis may lead to an increase in incidence of postoperative bleeding and with this an increase in acute compartment syndrome of the thigh following primary total hip arthroplasty. Onset of severe pain of the upper leg postoperatively should warrant a high index of suspicion of this condition. Diagnostic tools such as ultrasound, computed tomography or intra-compartmental pressure measurements can be useful but should not lead to any delay of treatment.

Hogerzeil DP, Muradin I, Zwitser EW, Jansen JA. Acute compartment syndrome of the thigh following hip replacement by anterior approach in a patient using oral anticoagulants. *World J Orthop* 2017; 8(12): 964-967 Available from: URL: <http://www.wjgnet.com/2218-5836/full/v8/i12/964.htm> DOI: <http://dx.doi.org/10.5312/wjo.v8.i12.964>

INTRODUCTION

Acute compartment syndrome (ACS) is a known complication often following trauma such as fractures or crush injuries. However, ACS of the thigh is an uncommon complication, which has not been reported before after hip replacement by anterior approach through the anterior supine interval. Known causes for ACS of the thigh include femoral fractures, acetabular or proximal femur surgery, tourniquet application and extensive deep vein thrombosis^[1-4]. With the current trend of more oral anticoagulants being used and perioperative bridging therapy using LMWH it is noted that postoperative bleeding and the hereby possibly inferred ACS may be on the rise.

CASE REPORT

A 69-year-old male, using oral anticoagulation medication (Fenprocoumon 3 mg) due to a history of stroke, underwent total hip replacement of the right hip using the anterior approach through the anterior supine interval, as treatment for his end stage osteoarthritis. Only uncemented materials were used. Following hospital protocol, the administration of oral anticoagulation (OAC) medication was discontinued 5 d before surgery and the patient was bridged using LMWH (Tinzaparin 18.000 IE, subcutaneously) as venous thromboembolism (VTE) chemoprophylaxis. Preoperatively the patients' international normalized ratio was 1.3. Additionally, tranexamic acid, as part of hospital protocol regarding postoperative hemorrhage prophylaxis, was administered intraoperatively. THA was performed without any complications. However, total intraoperative blood loss was 600 cc, slightly higher than average. This was attributed to the patients' regular use of anticoagulation medication and current bridging therapy. The night following the operation the patient complained of pain in the ipsilateral leg which was interpreted as postoperative pain for which additional opioids were prescribed. One day following surgery hemoglobin levels were 7.0 g/dL (Preoperative Hemoglobin levels were 9.4 g/dL). During the course of the day the patient needed additional opioids to perform routine exercises. However, during the evening the pain aggravated and additional opioids could not suppress the pain with progressing symptoms of swelling, hematoma and paresthesia of the right leg.

Ultrasound of the thigh was performed which showed an intramuscular hematoma of the anterior

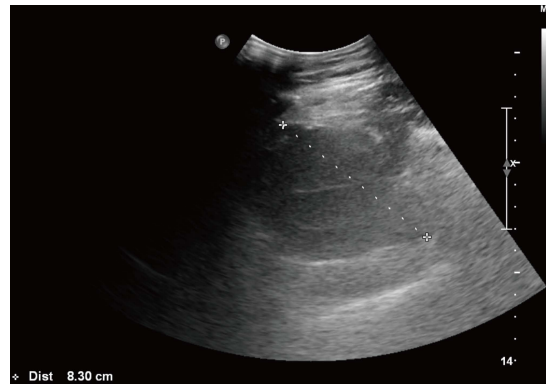


Figure 1 Ultrasound of the thigh showing an intramuscular hematoma of the anterior compartment.

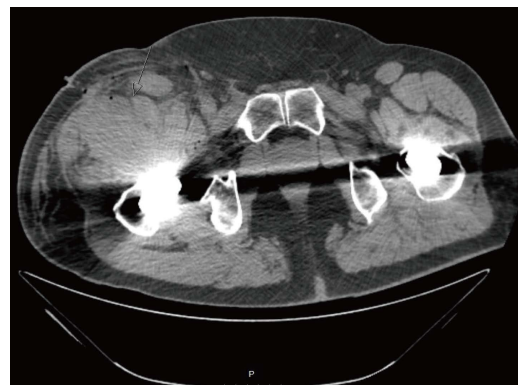


Figure 2 Transverse plane computed tomography scan showing a hematoma ventrally in the anterior compartment.

compartment of 8.3 cm by 3.5 cm (Figure 1). Additional computed tomography (CT-scan) was performed which confirmed the diagnosis and showed 2 hematomas of the anterior compartment (Figures 2-4). No intra-compartmental pressure measurements were performed as the diagnosis had already been confirmed and would only have delayed treatment. Delay of diagnosis in this case can be attributed to the fact that the patients' need for additional opioids to perform routine exercises one day postoperatively is not an uncommon occurrence. Furthermore, the first postoperative Hemoglobin levels were slightly decreased (7.0 g/dL), however within acceptable postoperative range and thus warranted no further investigation at the time.

To prevent further expansion of the hematoma VTE prophylaxis was discontinued and an emergency fasciotomy through the anterior compartment of the thigh was performed. A large hematoma was evacuated, the surgical site was extensively irrigated with normal saline solution and tranexamic acid was administered topically in the wound. Cultures of the surgical site showed no infection. The following day postoperative hemoglobin levels were at 3.9 g/dL for which the patient received multiple 4 blood transfusions over the course of several days after which hemoglobin levels were normalized to 7.3 g/dL.

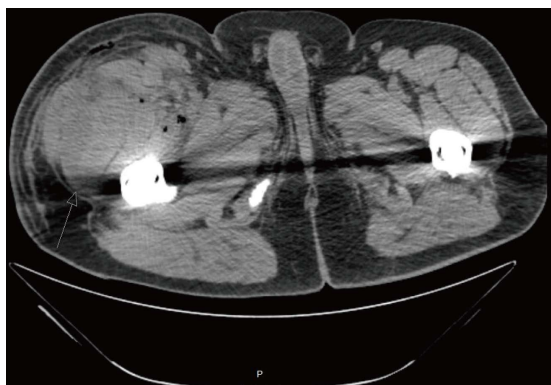


Figure 3 Transverse plane computed tomography scan showing a hematoma dorsally in the anterior compartment.

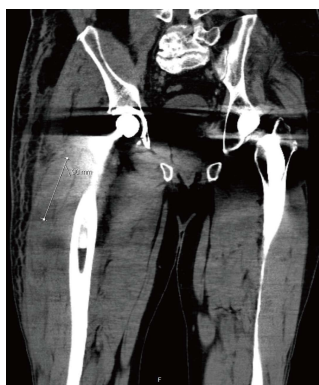

Figure 4 Coronal plane computed tomography scan showing a hematoma of the anterior compartment.

Directly after emergency fasciotomy the neurological deficit and the severe pain the patient had previously been experiencing, disappeared. Over the next few days mobilization was increased and at 6 d after emergency fasciotomy patient was discharged with low dose LMWH (Nadroparin 2850 IE, subcutaneously) as VTE prophylaxis. 11 d after emergency fasciotomy OAC therapy was resumed without any further complications.

At 8 and 12 wk follow-up, the patient did not have signs of any residual neurological deficit.

DISCUSSION

ACS is defined by increased pressure in a closed fascial space compromising the circulation to the nerves and muscles within the involved compartment^[5]. ACS in the thigh is a rare complication following primary THA. This can be due to several reasons.

From an anatomical perspective, it could be explained by the large volume of soft tissue of the thigh, therefore requiring extravasation of a large volume of fluid to cause compression of local structures^[3]. Aside from the large volume of the three compartments in the thigh, the fascia of the thigh seems to be more dilative compared to the fascia of the lower leg^[6]. Furthermore, the compartments of the upper leg are partly open to the pelvis explaining the higher compensation space for

increasing an intra-compartmental hematoma^[7].

Literature shows cases with ACS both shortly after operation as well as several days following THA, the common denominator often being VTE prophylaxis^[3,4,8]. It is our belief that in our patient, the increased intra-compartmental pressure was most likely caused by iatrogenic laceration to the branches of the circumflex femoral arteries aggravated by his regular use of anticoagulation medication and current bridging therapy. We noticed that the ACS progressively developed during the postoperative mobilization, which possibly severed the vessels during exercise. The classical sign of ACS, *i.e.* disproportionate pain, is difficult to judge in a patient after THA in which opiates are regularly required. However due to the alertness of the nurse staff and ward physician the diagnosis was confirmed shortly after the paresthesia developed, which prevented permanent neurological and vascular damage.

ARTICLE HIGHLIGHTS

Case characteristics

A 69-year-old male presented with severe pain, swelling, hematoma and paresthesia of the right leg following elective total hip replacement by anterior approach.

Clinical diagnosis

Severe pain, swelling and hematoma of the upper leg, as well as paresthesia of the lower leg.

Differential diagnosis

Postoperative pain, postoperative dislocation of the hip, periprosthetic fracture, iatrogenic neurological damage.

Laboratory diagnosis

Preoperative international normalized ratio was 1.3 and Hemoglobin level 9.4 g/dL, postoperative Hemoglobin levels were 7.0 g/dL and 3.9 g/dL.

Imaging diagnosis

Ultrasound of the thigh showed an intramuscular hematoma of the anterior compartment of 8.3 cm by 3.5 cm and computed tomography revealed two hematomas of the anterior compartment.

Pathological diagnosis

Cultures of the surgical site showed no infection.

Treatment

Venous thromboembolism (VTE) prophylaxis was discontinued and an emergency fasciotomy through the anterior compartment of the thigh was performed during which a large hematoma was evacuated, the surgical site was extensively irrigated with normal saline solution and tranexamic acid was administered topically in the wound.

Related reports

Acute compartment syndrome is a known complication often following trauma such as fractures or crush injuries. However, a highly uncommon presentation and localization of acute compartment syndrome is that of the thigh following total hip replacement by the anterior approach. The first symptoms of acute compartment syndrome of the thigh can easily be confused with other causes for postoperative pain, swelling, hematoma and paresthesia.

Term explanation

Acute compartment syndrome is defined by increased pressure in a closed

fascial space compromising the circulation to the nerves and muscles within the involved compartment. VTE prophylaxis is a mechanical or pharmacologic method for prevention of venous thromboembolism.

Experiences and lessons

Acute compartment syndrome of the thigh is a highly uncommon complication following total hip replacement by anterior approach and as such should and must be considered in case of postoperative onset of severe pain of the upper leg.

REFERENCES

- 1 **Kahan JS**, McClellan RT, Burton DS. Acute bilateral compartment syndrome of the thigh induced by exercise. A case report. *J Bone Joint Surg Am* 1994; **76**: 1068-1071 [PMID: 8027116 DOI: 10.2106/00004623-199407000-00017]
- 2 **Rahm M**, Probe R. Extensive deep venous thrombosis resulting in compartment syndrome of the thigh and leg. A case report. *J Bone Joint Surg Am* 1994; **76**: 1854-1857 [PMID: 7989391 DOI: 10.2106/00004623-199412000-00013]
- 3 **Mar DD**, MacDonald SJ, Bourne RB. Compartment syndrome of the right anterior thigh after primary total hip arthroplasty. *Can J Surg* 2000; **43**: 226-227 [PMID 10851420]
- 4 **Elsorafy KR**, Jm Stone A, Nicol SG. Acute compartment syndrome of the thigh 10 days following an elective primary total hip replacement. *Ortop Traumatol Rehabil* 2013; **15**: 269-271 [PMID: 23898004 DOI: 10.5604/15093492.1058422]
- 5 **Lipson SJ**, Mazur J. Anteroposterior spondyloschisis of the atlas revealed by computerized tomography scanning. A case report. *J Bone Joint Surg Am* 1978; **60**: 1104-1105 [PMID: 721859 DOI: 10.2106/00004623-197860080-00012]
- 6 **Schwartz JT Jr**, Brumback RJ, Lakatos R, Poka A, Bathon GH, Burgess AR. Acute compartment syndrome of the thigh. A spectrum of injury. *J Bone Joint Surg Am* 1989; **71**: 392-400 [PMID: 2925712 DOI: 10.2106/00004623-198971030-00013]
- 7 **Burghardt RD**, Siebenlist S, Döbele S, Lucke M, Stöckle U. Compartment syndrome of the thigh. A case report with delayed onset after stable pelvic ring fracture and chronic anticoagulation therapy. *BMC Geriatr* 2010; **10**: 51 [PMID: 20663221 DOI: 10.1186/1471-2318-10-51]
- 8 **Nadeem RD**, Clift BA, Martindale JP, Hadden WA, Ritchie IK. Acute compartment syndrome of the thigh after joint replacement with anticoagulation. *J Bone Joint Surg Br* 1998; **80**: 866-868 [PMID: 9768900 DOI: 10.1302/0301-620X.80B5.8324]

P- Reviewer: Fenichel I **S- Editor:** Cui LJ **L- Editor:** A
E- Editor: Lu YJ





Published by **Baishideng Publishing Group Inc**
7901 Stoneridge Drive, Suite 501, Pleasanton, CA 94588, USA
Telephone: +1-925-223-8242
Fax: +1-925-223-8243
E-mail: bpgoffice@wjgnet.com
Help Desk: <http://www.f6publishing.com/helpdesk>
<http://www.wjgnet.com>

